

# Henna and the Evil Eye, Salt and Demons, and the Geography of G6PD Deficiency

Catherine Cartwright-Jones

## Abstract:

Traditions of averting malevolent spirits with henna and salt to may have altered the incidence of Glucose-6-phosphate dehydrogenase deficiency in populations across the North Africa, the Levant, and the Arabian Peninsula. The geographic distribution of G6PD deficiency, an x-linked hereditary enzymopathy, has been correlated to populations' adaptation to malarial environments, but this has not fully explained the variations in the gene's distribution. For instance, Jewish Sephardim and Mizrahim have 30% to 60% of G6PD deficiency while Muslims from the same countries have rates of 1.8% to 8.5%. Recently, physicians have found that G6PD deficient neonates and young children, particularly males, who have been hennaed according to local blessing and curing traditions in Turkish and Bedouin Muslim cultures, suffer hyperbilirubinemia and acute hemolytic crisis. In Jewish traditions in the same regions, children were traditionally rubbed with salt rather than henna. This paper proposes that traditions of using henna versus salt as celebration and folk remedies for children may have changed the genetic prevalence of G6PD over generations.

## Keywords: Henna, salt, G6PD-deficiency, malaria

Traditional practices meant to prevent the Evil Eye and Lilith from killing infants may have caused the divergence in G6PD deficiency rates between Jewish and Muslim populations across North Africa, the Arabian Peninsula, the Levant, and the Middle East.

Malevolent spirits were often blamed for death and disease in the thousands of years that preceded the understanding of bacteria, viruses, and genetic disorders. People widely believed the Evil Eye to be a deadly and disabling force across North Africa, the Arabian Peninsula, the Levant and Southwestern Asia (Dundes, 1980). Scripture and persons also attributed illness and death to predatory supernatural sprits. Each religious and local group had slightly different narrations of these dangerous forces. Each religious and local group had slightly different treatments, prayers, and magical symbols to protect themselves. Traditional treatment of disease involved both plant and mineral based therapies, coupled with prayers and symbols to avert the Evil Eye and demons.

Henna, *lawsonia inermis*, was generally believed to be beneficent, and specifically to avert the Evil Eye. Henna was applied to skin in culturally significant patterns, or broadly as a curative. Beautiful children were believed to especially vulnerable to attack by the Evil Eye.



**Figure 1 Hand Stained with Henna**

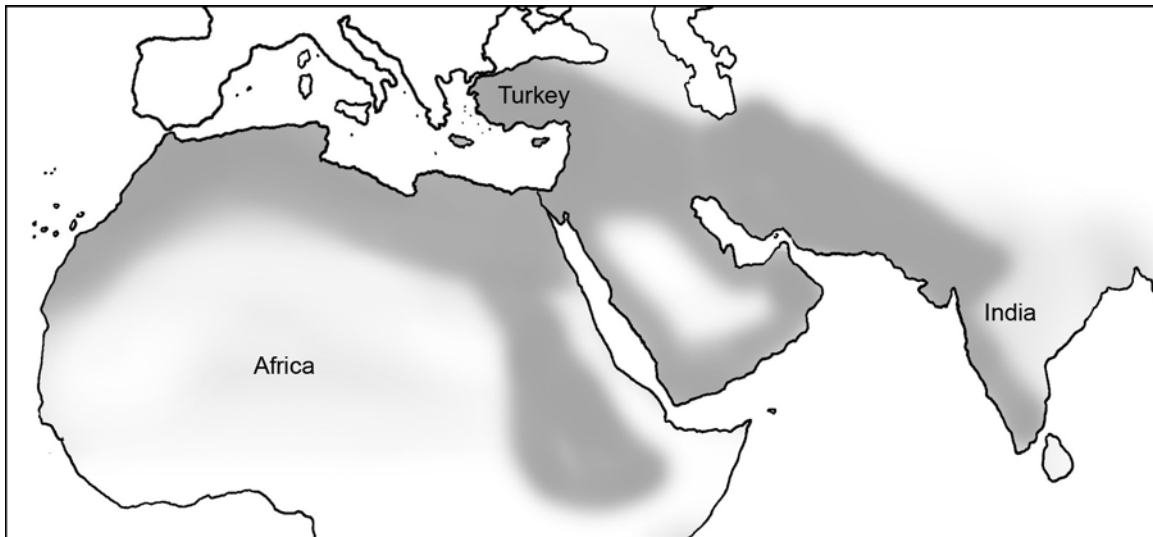
Salt was also believed to be beneficent, and to deter supernatural spirits that brought sickness and death. One such demon to be averted was Lilith, named and described as a specific threat to infant males in the Talmud. Lilith is linked to early Hebrew לילית Lilit, and Akkadian Līlītu, lascivious predatory female supernatural spirits, and Lilith was identified as a dangerous spirit in Jewish culture during the biblical period.

Traditions of averting malevolent spirits with henna, *lawsonia inermis*, and salt may account for anomalies in the population geographies of G6PD deficiency. The management of children's health is reflected in the subsequent generations, as children whose mortality is successfully managed will live to reproduce. The risks to children are culturally conceived, and managed or cured with whatever resources are available. If malevolent spirits are considered to be the source of children's illness and death, then the management of malevolent spirits affects population geography. The Evil Eye was once blamed for sickness and death across North Africa, the Arabian Peninsula and the Levant. In Talmudic traditions in these same areas, death of male children was once blamed on the demon Lilith. Henna was believed to avert the Evil Eye. Lilith was believed to be attracted to henna but averted with salt and henna's complimentary opposite: indigo. The parallel traditions of protecting infants with henna and salt both had some health benefit. Both brought some risk to a child. One specific risk is that henna can be fatal to an infant with homozygous G6PD deficiency; salt is not.

## Looking Beyond Malaria

The rate of genetic Glucose-6-phosphate dehydrogenase deficiency in a population has been theorized to be an adaptive response to malaria (Greene, 1993). G6PD deficiency offers some protection against malaria, as does sickle cell anemia: malaria is more often fatal in persons with normal G6PD enzyme production. This theory generally fits the geographic dispersal of G6PD deficiency, but there are some inconsistencies. There is a striking difference in rates between Jewish populations who lived in North Africa, the east coast of the Mediterranean, Turkey, the Middle East, and Yemen (see Figure 1), and Muslim populations who lived alongside them prior to the Ingathering in Israel. Jews descended from these areas have G6PD deficiency rates of 30% to 60% (Kaplan and Abramov, 1992). Muslims from these areas have G6PD deficiency rates of 1.8% to 8.5% (Nair et al, 2008). Presumably, mosquitoes are indifferent to their hosts' religion and culture, and feed upon all persons equally. Therefore, the differing rates of G6PD deficiency in these populations cannot be explained by a simple development of malarial resistance.

The answer to differing G6PD deficiency rates may be found in the intersection of information from anthropology, folklore and folk medicine with medical geographic studies of G6PD deficiency distribution and hospital admissions of children with G6PD deficiency-based hemolytic crisis.



Edot HaMizrach, Temani and Maghribiyyun Jewish Communities Before 1930

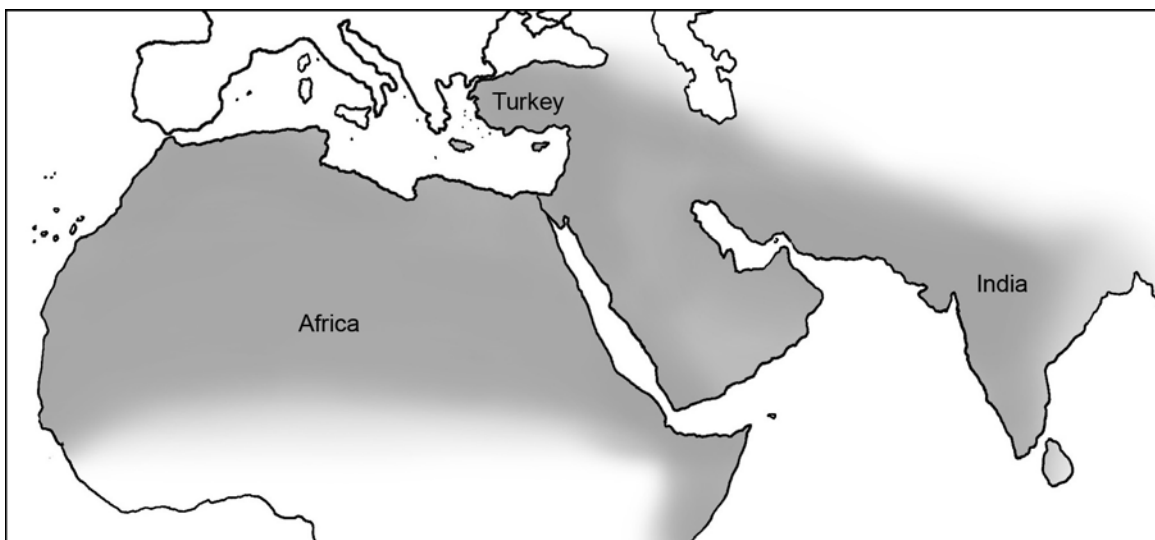
**Figure 2: Map of North Africa, eastern Mediterranean, Turkish, Yemeni, and Middle Eastern and South Asian Jewish communities living within majority Muslim populations prior to 1930.**

Genetic differences are often viewed as evidence of ancient environments and adaptations to those environments. Many geneticists believe that the varying prevalence of G6PD deficiency population is a reflection of adaptation to malarial environments (Greene, 1993; 153). This does not explain how two different cultures living in the same place, suffering same epidemics of malaria stressors, would have different rates of G6PD

deficiency. For Jews to have rates of 30% to 60% and Muslims to have 1.8% to 8.5% after living for centuries together in the region shown in Figure 1, something other than an adaptive response to malarial environments must have affected mortality.

Genetic differences are often viewed as footprints of migrations as people with a definable gene pool moved to another region and settled. Persons carrying a variant of G6PD deficiency originating in a distant region have been hypothesized to be a demonstration of the person's ancestors having migrated from that region (Koeta et al, 1999; Tripathy and Reddy, 2007; and Matsuoka et al, 2003). Both Jews and Muslims have circulated through the region in Figure 1, but their ancestors inhabited the region for centuries. There are no recent Jewish or Muslim immigration from regions with differing G6PD deficiency rates, such as the case in Mauritius (Koeta et al, 1999) that would account for the divergence.

Genetic differences can also arise from ancient behavior, because behavior can affect mortality. Increased incidence of genetic lactose tolerance in populations with dairy cows is favored through increased survival of children who continue to drink milk past infancy (Smith, 2007). If a behavior lowers mortality in juveniles, the genes of those children are replicated in future generations, such as the genetic ability to digest milk. If a behavior raises mortality in juveniles, those children's genes are removed from future generations.



Regions of Henna Habitat and Traditional Use

**Figure 3: Area where henna, *lawsonia inermis*, is an indigenous plant and has been used for body art, hair dye, and household remedies.**

Henna use is widespread, has been used for centuries and is generally considered harmless. However, there are certain instances where it could affect infant mortality. Figure 2 is a map of the region where henna is an indigenous plant, and where henna was used for celebration, adornment, and maintenance of health and appearance for centuries,

“Henna and the Evil Eye, Salt and Demons, and the Geography of G6PD Deficiency” was prepared by Catherine Cartwright-Jones for GEOG-80998-002-200880, in partial fulfillment of requirements for PhD studies to Dr. J Tyner PhD, Geography Department, Kent State University, 2008

with evidence from as early as the Bronze Age. The Jewish and Muslim groups discussed in this paper fall within the henna-using region shown in Figure 2. These populations had access to and were generally in the habit of using henna for celebration, hair dye, and household remedies.

Anthropological and folk literature describes traditions of large henna applications to infants and juveniles celebrating their births and birthdays, which continue to the present. We have current hospital records showing that these henna applications can cause severe hyperbilirubinemia and death in infants and juveniles with homozygous G6PD deficiency (Raupp et al, 2001). If extensive henna applications to G6PD deficient infants are fatal at present, they must have been fatal in the past. If children died in the past from henna applications, those children's genes would have been excluded from the population. A group that has had such a traditional henna practice for many generations would be expected to have a low incidence of G6PD deficiency. If neighbors living alongside them had different traditions, and did not apply henna to their children, their G6PD deficient individuals would have survived to reproduce. In a malarial region, these children would have had the advantage of surviving malaria epidemics, and their G6PD deficient genes would have contributed to their reproduction in subsequent generations.

Of course, we do not know precisely what the levels of G6PD deficiency, malaria, and henna use on infants were through centuries of life in the regions mapped in Figure 1. When large datasets of ancient environments, mortality, behaviors and blood types do not exist, theorizing the reason for genetic similarity and diversity is often limited to inference from applying logic to shreds of evidence (Greene, 1993; 163). In the subsequent sections of this paper, I bring what support I can to my proposal that henna traditions were negatively affecting the prevalence of G6PD deficiency in populations while malaria was positively affecting the prevalence.

### **Glucose-6-phosphate dehydrogenase deficiency**

G6PD deficiency is a genetically inherited human enzyme defect, affecting more four hundred million people across the world. It is an enzyme deficiency caused by mutation on the G6PD gene: there are about 400 mutation variants presently described. The G6PD deficient person has a natural resistance to malaria: parasitization by *Plasmodium* is slowest in G6PD-deficient cells. Plasmodium consumes the red blood cell enzyme produced by G6PD, and if that enzyme is deficient, the plasmodium fails to thrive and parasitize the host. The G6PD-deficient person is therefore resistant to malaria (Tripathy and Reddy 2007).

G6PD deficiency is X-linked. Because it is X-linked and may be hemizygous or heterozygous in females, and they may be carriers without suffering from the disease; patients presenting with anemia and hemolytic crisis are almost exclusively male and homozygous G6PD deficient. The homozygous G6PD deficient person is vulnerable to oxidative hemolysis: large applications of henna can cause hemolytic crisis in homozygous G6PD deficient infants and juveniles (Raup et al, 2001).

Malaria is regarded as a positive critical evolutionary agent for increasing the G6PD deficiency rates in a population, while substances causing oxidative hemolysis are critical evolutionary agent for decreasing the rates (Simoons, 1998). If a malaria epidemic engulfs a community, G6PD deficient children are more likely to survive because they are genetically resistant, so rates of G6PD deficiency will be increased in the subsequent generation. If henna is applied to children, causing hemolytic crisis (particularly to males) before puberty, G6PD deficiency rates will be decreased in the subsequent generation.



**Figure 4: Henna, *lawsonia inermis***

### **Henna: Blessing and Curing**

The henna plant, *lawsonia inermis*, and use of that plant is widespread from the Atlantic coast of North Africa through the Arabian Peninsula, the countries bordering the eastern Mediterranean, the Middle East, and South Asia as shown in Figure 2, and there is evidence for henna use across this region for up to 5000 years. Henna is an important part of the cultural life in these area, where is generally considered beneficial and lucky. Henna is used for celebratory body decoration and for everyday appearance: people use henna to dye their hair and fingernails as well as ornamenting their skin with henna patterns. Henna is also a folk remedy for headache (Johnstone, 1998, p.63), head lice (El-Basheir and Fouad, 2002), ringworm (Bosoglu et al, 1998), diaper rash (Katar et al, 2006), skin rash (Kok et al, 2004 and Soker et al 2000), burns (Muhammad and

Muhammad, 2005), heat exhaustion, cuts, boils, and fever reduction (Saksena, 1979: 96). Henna applications have a high level of safety, with little evidence of harm except to G6PD deficient neonates and children, particularly males.

Traditionally, henna leaves are pounded, sifted, mixed with a mildly acidic liquid, and this paste is spread on the skin. The dye in henna leaves, lawsone, penetrates and stains the epidermis an orange, red, or brown color. Though most of the dye remains in the stratum corneum, about 1% penetrates into the blood-bearing layer of skin (Kraeling and Bronaugh, 2007). This is harmless for most people, though lawsone will cause oxidative hemolysis in G6PD deficient blood cells. The skin of infants and children is generally thinner and more permeable than adult skin, permitting a greater and more dangerous uptake for G6PD deficient juveniles (Ya-Xian et al, 1999)



**Figure 5: Hand stained with henna**

### **Malarial Environmental Theory and G6PD Deficiency in Sephardic and Oriental Jews and their Muslim Neighbors**

G6PD deficiency is generally geographically positively correlated with a malarial environment, and is believed to protect carriers against malaria (Cappellini, 2008, p. 64).

“Henna and the Evil Eye, Salt and Demons, and the Geography of G6PD Deficiency” was prepared by Catherine Cartwright-Jones for GEOG-80998-002-200880, in partial fulfillment of requirements for PhD studies to Dr. J Tyner PhD, Geography Department, Kent State University, 2008

Jews and Muslims, who lived alongside each other for centuries in North Africa and the Levant, were presumably stressed equally by malaria. Jewish Kurdish males have over 58.2% G6PD deficiency (Kaplan and Abramov, 1992), but their Muslim neighbors in Turkey and Iraq have 3% to 10% deficiency (Livingstone, 1973; Hamamy and Saeed, 1981). Sephardic and Oriental male Jewish infants whose ancestors lived the region shown in Figure 1, were tested for G6PD deficiency at a well baby nursery were found to have an aggregate G6PD deficiency rate of 34.9%. The Center for Arab Genomic studies found that Muslims presently living in the countries from which these Jewish children's families migrated had aggregate rates between 0.6% (Yemen) to 4.5% (Egypt) (Nair et al, 2008).

The groups with 10% or lower rates of G6PD deficiency have traditions of using henna to bless an infant and to cure some common diseases of childhood. The Jewish groups with 30% and higher rates G6PD deficiency used salt instead of henna to bless children and soothe some ailments. Both groups adorned brides with henna for weddings, and women in both groups used henna dye gray hair, and to color their soles, fingertips and fingernails. If malaria should have exerted similar pressures on people living alongside each other, tending to raise the rates of G6PD in a population, differing use of henna on infants might have caused diverging rates.

### **Demons, Blessedness, and the Parallel Traditions of Salt and Henna**

Across North Africa and the Levant, traditional concepts of blessedness and damnation, purity and pollution, protection and vulnerability, existed for centuries in indigenous cultures and religions including Islam, Judaism and Christianity. These polar concepts permeated the understanding of nature and life, and were reflected in religion, medicine, law and daily practice. Some substances, such as salt, henna, incense, running water and silver were believed to have an inherent blessedness that could protect one against the malevolent, threatening aspects of the world. These were often said to have *baraka*, blessedness, parallel to the Hebrew word *baruk*. Other substances, such as excreta, blood, stagnant water, and corpses were believed to be inherently threatening to well being. Positive forces such as saints and angels also had blessedness, and were considered capable of healing. Negative forces such as the Evil Eye and demons were threatening, and were believed capable of causing illness or death. Ancient Assyrian and Babylonian physicians who described diseases so accurately that they can be easily recognized now, frequently ascribed the cause of an illness to a malevolent spirit: *Kubu* was a demon that was the manifestation of a stillborn child (Scurlock and Anderson, 2005: 387), a child who died of choking was strangled by a *Lilu* demon (ibid: 414). The beliefs in supernatural causes of wellness and disease were not primitive ignorance, they reflected the vulnerabilities of life and death, and were a working explanation for natural phenomena (Klein, 2000). Prayers, amulets, and actions to avert demons accompanied medicines and medical procedures.

Salt was seen as essential to life, as having *baraka* or *baruk*, and a blessed thing. Salt was believed to be capable of averting malevolent spirits. One term for *jnun*, malevolent spirits, was *willi-tntl-tisnt*, or “those who shun salt”. The malevolent spirits were a



supernatural, invisible race of beings parallel to humans. They had no physical bodies, but they were able to affect the physical world. *Jnun* ate and drank, but they would not drink water or eat food with salt (Westermarck 1926, I: 263 - 4). Malevolent *jnun* were irresistibly attracted to blood. When food without salt spoiled rapidly, the spoilage was attributed to *jnun* were eating and fouling it. The spirits were repelled from salted food, so salted food stayed fresh longer. *Jnun* caused infections, withering, and illness when they entered the body through exposed blood. If wounds and rashes were washed frequently with salt water (as saline solution is used now) the blood seeking *jnun* were averted, and the wound did not become infected.

Henna was believed to have *baraka*, and was used to bless, adorn, cleanse, and as a folk remedy for skin problems. Westermarck, in "Ritual and Belief in Morocco"(1926), offers nearly a hundred examples of the use of henna to bless, protect, and avert the Evil Eye: the Evil Eye being often held responsible for illness and death (Chapter VIII). He lists a similar number of examples for salt. Other anthropologists recorded the same beliefs, and found similar ones held across the region clear to South Asia, not just in Morocco.

Henna is best known, and most widely used, to adorn the bride, guests and family at a marriage. Henna has been used for that since the Bronze Age in the Eastern Mediterranean, when texts from Ras Shamra described women hennaing their hands before going to seek their husbands (De Moor 1971: 85). There are enough records of this existing to propose that this tradition has been generally constant through the centuries, and was widely practiced through the region by Jews, Christians, animists as well as Muslims, with whom the "Night of the Henna" is most closely associated. Records of Jewish traditions in the region describe the traditions of Jewish brides hennaed for their weddings, and for community celebrations (Iran: Goldin, 2003: 48 – 50; Algeria and Morocco: Rubins, 1967: 74 and 80; Kurdistan: Brauer, 1993: 119 - 126).

Westermarck (1926) and Hammoudi (1993) described widespread henna use for religious holidays such as Eids and Purim (Brauer 1993, 348 - 9). Henna was part of social and ceremonial life through the region for Muslims and Jews alike.

The most common use of henna was by adults to dye hair and mask the appearance of ageing. There evidence for this practice from dynastic Egypt until present: mummies have been found with hennaed hair and hennaed fingernails. Ritual bathing at the end of the menstrual cycle was required in Jewish and Muslim practice. At the monthly ritual post-menstrual bath, both Jewish and Muslim women applied henna to their hair, hands and feet at the village baths. Henna rid their hair of lice, dandruff, and covered the gray. Henna on their feet treated fungal infections. Henna was an essential part of women's monthly practice for all women who could afford it throughout the region, with the practice being continuous from before the Roman era to the present. Henna use by adults for auspicious body markings and hair dye seems to cause no harm and was seen as appropriate and beneficial.



**Figure 6: Hand and fingernails stained with henna patterns to avert the “Evil Eye”**

Henna was also used in folk medicine, and was recommended in early Muslim medical texts such as “The Medicine of the Prophet” for specific illnesses. Henna was applied to feet and hair to relieve migraines. Henna was chewed to cure mouth ulcers, leg pain, and to relieve skin inflammation. If henna was used for these ailments harmlessly and beneficially on adults, then parents might assume it could be used on their children. Henna was used to cure thrush in infants, rubbed over their bodies to cure scabies, mixed with oil to treat burns, applied to children in early stages of smallpox, and applied to their hair to cure lice, dandruff and ringworm (Al-Jawziyya, 1998: 64-5). Though the curative powers of henna were attributed to its blessedness and ability to thwart malevolent supernatural forces, henna has been demonstrated to be genuinely anti-fungal, anti-inflammatory and effective against some bacteria (Muhammad and Muhammad, 2005) (Ali, et al, 1995).

Henna applications to post-pubescent individuals do not seem to be life threatening. In current published medical papers external henna applications causing hemolytic crisis, no individual is older than 10 years old. Henna applied to female children is unlikely to cause hemolytic crisis, because G6PD deficiency is x-linked, so girls are more likely to be heterozygous or hemizygous. A mother might have assumed that if henna on her skin was harmless and beneficial, it should be harmless and beneficial to her son. If she were a hemizygous or heterozygous carrier of G6PD deficiency, her son might suffer hemolytic crisis from henna if he was born homozygous G6PD deficient. The fatality might be

attributed to supernatural causes, such as a particularly malevolent spirit or the Evil Eye. Those henna applications that were fatal to children would have changed lowered the group rate of G6PD deficiency, because their pre-pubescent death removed their genes from the next generation.

Most of the social applications of henna would have been harmless. Westermarck and others describes the henna application for Eid as being a few dots on the hands. Children might get a bit of henna at a family wedding, but never as much as the bride. Boys were never accorded as much henna as girls, usually being limited to a single finger stained with henna.

Though most henna applications seemed harmless and beneficial, others were potentially fatal to the relatively few vulnerable individuals, comparable to the ones seen in published papers on hospital admissions of hennaed G6PD deficient children in hemolytic crisis.

### **Folk Medicine, Celebration, Henna and Hemolytic Crisis**

Recently, medical papers have detailed deaths and near deaths of children to whom henna was applied over large body areas. The following are cases from hospitals in UAE, Turkey and Oman, where henna is traditionally applied in events of celebration and joy, and as a household remedy for minor ailments.

- 1) A seven-day-old boy developed jaundice and pallor twenty-nine hours after application of henna to 50% of his body as a treatment for diaper rash (Katar et al, 2006).
- 2) A twenty-day-old G6PD deficient girl developed jaundice, pallor, and dark urine twenty-four hours after her mother applied henna over her entire body (Raupp et al, 2001). She recovered after two exchange transfusions.
- 3) A two-month-old male G6PD deficient developed jaundice, pallor, and dark urine forty-eight hours after his mother applied henna to his palms and soles; two days later he was admitted to the hospital in shock, and died two days after that. (Ibid) Physicians estimated that henna was applied to 20% of this male infant's body surface.
- 4) A three-year-old G6PD deficient boy developed jaundice, pallor, and dark urine after his mother applied henna to his feet. He recovered after transfusion. (Ibid) This henna application would have been about 10% percent of body surface.
- 5) A four-year-old G6PD deficient girl had henna applied to palms and soles, and developed jaundice, pallor, and dark urine within two days. She recovered within a week (Ibid). This henna application would have been about 20% percent of body surface.

6) In Turkey, a twenty-seven day old G6PD deficient boy developed jaundice, pallor, and dark urine four days after henna was applied over his belly and legs to treat diaper rash; the child died within three days. (Devecioglu et al, 2001) This henna application would be about 50% of body surface.

7) Siblings, an eleven-year-old G6PD deficient male and a seven-year-old G6PD deficient female developed jaundice, pallor, and dark urine six hours after their mother applied henna over 100% of their body surfaces to treat skin lesions. They were given transfusions; the boy survived, but the girl died two days after. (Kok, et al, 2004)

8) An eleven year old G6PD deficient boy was admitted to hospital with jaundice, dark urine and pallor a day after his mother applied henna over 100% of his body surface to treat skin lesions. After transfusions, the child recovered (Soker et al, 2000).

The fatal, or nearly fatal cases all involve henna applications to large areas of the body, to very young children and infants. Male homozygous G6PD deficient infants seem to be the most vulnerable. Larger applications seem more likely to be fatal than smaller applications, and younger infants seem to have higher mortality than older children. If we may assume that parents who applied the henna were following local tradition, we would conclude that other children were surviving the same customs, and their parents applied the henna to their children with the expectation that it would be harmless, or helpful, not fatal.

If there are descriptions from the past that would indicate these practices have been widespread and long-held, the present-day hospital admissions could be shown to be a reflection of a process that inadvertently eliminated infants with homozygous G6PD deficiency for generations. Anthropological evidence for these practices is abundant:

1) From a description of childbirth in Siwa Oasis, Egypt, “After the child is named, everybody may look at the baby; then the midwife marks the cheeks, nose and legs of the infant with a paste of red henna” (Fahkry, 1973: 52).

2) Westermarck describes several observations in Morocco of ceremonial henna at infants’ birth for protection against malevolent supernatural beings and the Evil Eye. “In Fez, on the day after the birth of the child and on the two following days as well, the midwife rubs its body with with a mixture of henna, sugar, alum, marjoram, mint, mastic, water and a small quantity of oil, “in order to strengthen its skin” (Westermarck, 1926, 1: 383). “The body of the baby is ... painted with henna all over, “to prevent its catching cold”. “The Ait Waryagar have the custom of smearing henna on the top of the child’s head on the day after its birth, “to make the head strong” (Ibid, 384). “(On the seventh day) she (the midwife) also smears henna on the head, neck, navel, feet, and fingernails of the baby, and in its armpits and between its legs. I was told that this painting with henna, like

all other henna ceremonies, is intended as a safeguard against Jnun and the Evil Eye (Ibid, 389). “Among the Ait Waryager, when an infant has become forty days old, its crown is smeared with henna as a protection against fleas, lice, and the Evil Eye, and this is frequently repeated until it grows older. (Ibid, 2: 443)

3) Aida Bamia, from her field research in Algeria, described, “As soon as the infant is born, an imam (a religious figure in charge of observances inside and outside the mosque) whispers Qur'anic verses into the child's ear. The recitation of prayers marks all ceremonies, whether joyous or sad, in an Algerian Muslim's life. Shortly after birth, the child is covered with henna, and its whole body rubbed with olive oil. It is given a mixture of ground cumin and sugar candy to suck. (Bamia, 1988)

Full body or large application of henna use to avert the Evil Eye, celebrate birth, presentation to the community, six-month celebration and birthday would probably be fatal to an otherwise healthy homozygous or male G6PD deficient infant. Application of henna to 50% or more of a child's body surface or ingestion to cure the common ailments of ringworm, thrush, skin infection, burns, head lice, fever, and headache would also have been fatal. In the current medical reports of hemolytic crisis from henna applied to homozygous G6PD deficient infants, the children who survived did so because of intensive hospital care and blood transfusions. For the generations of children past, this was not available, and we may assume that those children did not survive. For children who were not homozygous G6PD deficient, the henna would probably provided needed relief from their ailments, been a marker of family celebration and tradition, done them no harm, and been seen as protecting them from malevolent supernatural forces.

It is not possible to be certain how consistently and widely these henna traditions were practiced, nor for how many generations. The datasets that would customarily be required for a study of medical geography cannot be recovered from history. We can only infer from what information we have that the practice of hennaing infants for birth and health was probably widespread and longstanding in the past. And, according to the Center for Arabic Genomic Studies Arabic, the populations in those regions do have very low rates of G6PD deficiency.

### **Salt and the Spirits Who Prey on Mothers and Infants**

Jewish families who once lived in North Africa, the Levant and the Middle East had different traditions of celebrating and treating infants. Evidence of cleansing infants with salt rather than henna may have been widespread in Jewish communities (Klein, 2000: 191-3) and practiced for at least twenty-five centuries. The comment, "Your father was an Emorite and your mother a Hittite, and as for your birth, on the day you were born your navel was not cut nor were you washed in water for cleansing, you were not salted at all nor were you swaddled...." (Ezekiel 16:4) certainly implies that Jewish infants were rubbed with salt or salty water to cleanse them after birth, and the neighboring groups did otherwise. Emorites and Hittites were Canaanite groups: henna was indigenous to that

region and Canaanite people used henna for celebration (Hooke, S. H., 1965; de Moor, 1971: 85). In Talmudic tradition, salt symbolized the Torah and God (Soferim xv. 8), because salt did not decay, and prevented decay. Salt was said to be as essential to life as God and the Torah were essential to life: no person could live without these. Salt dispelled malevolent spirits, who could not touch or consume salt. Salt was blessed, used to bless and to deter evil, just as henna was.

From biblical times until the early twentieth century, Jewish women in many communities bathed their newborns with salt, believing it would strengthen their skin, and avert the Evil Eye that might steal the life and strength from a child (Klein, 2000: 191). Salt would have helped the navel to heal and probably deterred some bacterial growth, but Jewish mothers in Yemen also believed it would help the infant to speak well as an adult, and Moroccan Jewish mothers only used salt to wipe their babies for the first week, waiting until the eighth day to bathe the child (ibid 193). Kurdish Jewish newborns were rubbed with salt rather than being bathed to insure the child would be healthy and strong (Brauer, 1993 p 157-8). A dull-witted or lazy person was chastised as not being properly “salted” as an infant. Hyperbilirubinemia can cause mental retardation, so a G6PD deficient child cleaned with henna might indeed suffer brain damage and be dull-witted.

Because G6PD deficiency is x-linked, any practice of henna on male infants would be particularly dangerous. In many Islamic communities, a boy’s hands and feet were hennaed for his circumcision (Fakhry, 1973: 53), but this circumcision typically was done between the age of four and twelve, beyond than the age of greatest vulnerability to oxidative hemolysis from henna. Jewish circumcisions took place on the seventh day after birth, an age very vulnerable to hemolytic crisis from henna (Raupp, 2001). In Kurdish Jewish traditions, henna was conspicuously absent from infant circumcision practices, though henna was included in many other family celebrations.

For circumcision in some Kurdish villages, the Jewish mother was protected with body art ceremonies parallel to those done for her night of the henna, but in this case to protect her from the demon Lilith, who preyed on women in childbirth and strangled infants. (Klein, 2000, 171 – 5) (Brauer, 162 – 168). Henna was avoided during birth and circumcision in the Jewish community so as to not attract Lilith. In Muslim communities, henna was often part of the celebration of birth and circumcision. In the Kurdish Jewish tradition, the woman was painted patterns with indigo vat (a fermented solution of indigo plant leaves, used to dye cloth blue), as a bride would have been stained with henna. This custom was called *rang kolkhila*, and the mother’s hands, feet and vulva were stained in blue patterns. The wall opposite her bed was painted in patterns, and the other women attending her were stained with blue patterns. The infant was painted with blue indigo patterns. The midwife struck the mother three times on the temples, and said “Depart, Lilith” to drive away the spirit who had come to steal the mother and son. Neither indigo nor salt would have had any affect on a child with G6PD deficiency. If a male infant had G6PD deficiency was hennaed to celebrate birth, the onset of hemolytic crisis and death might have been cognized as Lilith seizing and murdering the child. If the infant was

cleaned with salt and painted with indigo, his survival might have been attributed to the successful expulsion of Lilith.



**Figure 7: Arm stained with indigo patterns**

Over generations, the practice of using salt and indigo to avert Lilith may have contributed to a gradual proportional rising of G6PD deficiency in Jewish population, as the survivors of malaria epidemics carried gene. About 60% of Jewish Kurdish males in the twentieth century were G6PD deficient. Less than 10% of their Muslim neighbors carried the G6PD deficiency gene. One may infer, though not prove, that the different traditions of salt and henna created a divergence of G6PD levels in the two groups.

If one can suggest that the people living in these regions were at one time, perhaps in the Bronze Age, had relatively similar levels of G6PD deficiency, perhaps near the current global average of 12%, and groups had differing approaches to caring for their infants, averting predatory supernatural spirits, and celebrating their life, these divergent approaches of henna and salt coupled with malarial epidemics might have favored the increase or decrease of G6PD deficiency. It is certainly plausible that neonatal henna use removed homozygous G6PD deficient infants from population groups. Malaria certainly removed some infants who were not G6PD deficient.

The genotypes may have diverged gradually over the generations and the cultural practices solidified in reflection of this divergence. Families in groups with higher levels of G6PD deficiency may have seen incidences of sudden fever, bloody urine, pallor, rapid pulse and lethargy when henna was applied to a child, and they may have attributed this catastrophe as a demon, perhaps Lilith, seizing their child. These groups may have decided to avoid henna, preserving the incidence of G6PD deficiency, which then

protected the child during the next epidemic of malaria. Families in lower G6PD deficient groups may have seen little evidence of henna harming their children, while observing that henna cured head lice, skin rashes, ringworm and thrush, and helped burns heal. Most of those afflictions were not fatal, but were detrimental to the child's health and well-being. Parents usually avoid behaviors that increase the likelihood of the death of their infant in whom there is much care invested and potential hoped for, and repeat behaviors that give their child comfort and health. Use of or avoidance of henna may have passed over generations from observation to habit to tradition, and eventually left its mark on the groups' genotype.

There is, of course, no possibility of proving the theory that traditions of hennaing infants reduced G6PD deficiency in some population and that traditions of salting infants combined with exposure to malaria contributed to increased G6PD deficiency in other populations. Complete datasets of henna use and genotypes from past generations do not exist, and the theory cannot be ethically tested. However, inferences drawn from folk traditions, ethnographic records, and current hospital records do support the possibility that early childhood use of henna may have altered some of the genetic geographies of G6PD.

### **Conclusion:**

It is possible that the parallel traditions of henna and salt used to celebrate, cure, and protect infants from the Evil Eye and Lilith were crucial evolutionary agents in the geographies of G6PD deficiency. It is possible that traditional management of malevolent supernatural forces that were believed to prey upon children accounts for divergent levels of the gene in Muslim and Jewish populations in North Africa, Turkey, the Levant, Yemen and the Middle East. It seems certain that the simple correlation between G6PD deficiency levels and malaria presence is not a sufficient explanation.

There are groups that have a cultural practice of using henna on children who live alongside other groups that do not, such as Muslims and Jews, and these groups have different levels of G6PD deficiency. If henna was been used on children for generations to avert the Evil Eye in a group, henna probably decreased the incidence of G6PD deficiency in that group, because of homozygous G6PD children's death following henna application. If children were not hennaed, but were cleaned instead with salt or salty water to avert Lilith, the G6PD deficiency/malarial protection response favored increased G6PD deficiency in the population. The cultural practice of henna application to children can therefore have been a critical evolutionary agent lowering levels the levels of G6PD deficiency, with salt would be a neutral agent, and malaria is a critical evolutionary agent raising the levels of G6PD deficiency in a group.



## References:

- Ali BH, Bashir AK, Tanira MOM. 1995. Anti-inflammatory, antipyretic, and analgesic effects of lawsonia inermis L. (henna) in rats. *Pharmacology* **51**: 356–363
- Al-Jawziyya IQ, tr. Johnstone P. 1998. *Medicine of the Prophet*. The Islamic Texts Society: Cambridge, UK
- Bamia A. 1988. Al-Hayat al-Taqlidiyya: Traditional Life in Algeria *The World & I Online* **4**: <http://www.worldandi.com/specialreport/1988/april/Sa13575.htm> retrieved April 24, 2008
- Bosoglu A, Birdane F, Solmaz H. 1998. The effect of henna paste in ringworm in calves. *Indian Veterinary Journal* **75**: January
- Brauer E. 1993. *The Jews of Kurdistan*. Wayne State University Press: Detroit, Michigan
- Bryan C. 1974. *Ancient Egyptian Medicine: The Papyrus Ebers*. Ares Publishers Inc: Chicago, IL
- Cappelini M. 2008. Glucose-6-phosphate dehydrogenase deficiency. *The Lancet* **371**: 64 – 79
- Crane, F. ed. 1963. *The Lost Books of the Bible and The Forgotten Books of Eden*. World Publishing Company. Cleveland, Ohio.
- Devecioglu C, Katar S, Dogru O, Tas MA. 2001 Henna-induced hemolytic anemia and acute renal failure. *The Turkish Journal of Pediatrics* **43**: 65 - 66
- De Moor JC. 1971. *The Seasonal Pattern in the Ugaritic Myth of Ba'lu According to the Version of Ilimilku*. Neukirchen – Vluyn, Germany: Verlag Butzon & Berker Kevelaer
- Dundes, A. 1980. *Wet and Dry: The Evil Eye: An Essay in Indo-European and Semitic Worldview*. Interpreting Folklore 93 - 312. Indiana University Press
- El-Basheir M, Fouad MAH. 2002. A preliminary pilot survey on head lice, pediculosis in Sharkia Governate and treatment of lice with natural plant extracts. *Journal of the Egyptian Society of Parasitology*. **32**: 3
- Fakhry A. 1973. *Siwa Oasis*. The American University in Cairo Press.
- Goldin F, 2003. *Wedding Song: Memoirs of an Iranian Jewish Woman*. Brandeis University Press, Hanover and London

- Greene LS. 1993. G6PD deficiency as protection against *falciparum* malaria: an epidemiologic critique of population and experimental studies. *Yearbook of Physical Anthropology* **36**: 153 - 178
- Hamamy H, Saeed T. 1981. Glucose-6-phosphate dehydrogenase deficiency in Iraq. *Human Genetics*, **58**: 434 - 435
- Hammoudi A. 1993. *The Victim and Its Masks: An Essay on Sacrifice and Masquerade in the Maghreb*. University of Chicago Press: Chicago
- Hooke SH. 1965. *Middle Eastern Mythology*. Penguin Books: Middlesex, UK
- Johnstone P. 1998. *Ibn Qayyim Al-Jawziyya: Medicine of the Prophet*. Islamic Texts Society, Cambridge UK
- Kandil HH, al-Ghanem MM, Sarwat MA, al-Thallab FS. 1996. Henna (*Lawsonia inermis* Linn.) inducing haemolysis among G6PD-deficient newborns: a new clinical observation. *Annals of Tropical Paediatrics* **16** (4): 287-291
- Kaplan M, and Abramov A. 1992. Neonatal hyperbilirubinemia associated with glucose-6-phosphate dehydrogenase deficiency in Sephardic-Jewish neonates: incidence, severity and the effect of phytotherapy. *Pediatrics*, 90, 3: 401 - 405
- Katar S, Devecioglu C, Ozbek MN and Ecer, S. 2006. Henna causes life-threatening hyperbilirubinaemia in glucose-6-phosphate dehydrogenase deficiency. *Clinical and Experimental Dermatology* **32**: 325 - 236
- Kok, AN, Ertekin MV, Ertekin V, and Avci, B. 2004. Henna (*lawsonia inermis* Linn.) induced haemolytic anaemia in siblings. *International Journal of Clinical Practice* **58**, 5: 530 - 532
- Kotea R, Kaeda JS, Yan, SLK, Sem Fa, N, Beesoon S, Jankee S, Ramaswamy ., Vulliamy T, Bradnock, RW, Bautista J, Luzzatto L, Krishnamoorthy R, Mason PJ. 1999. Three major G6PD-deficient polymorphic variants identified among the Mauritian population. *British Journal of Haematology* **104**, 4: 849 – 854
- Matsuoka H, Jichun W, Hirai M., Yoshida S, Arai M, Ishii A, Baral MP. 2003. Two cases of glucose-6-phospahte dehydrogenase-deficient Nepalese belonging to the G6PD Mediterranean- type, not India-Pakistan subtype but Mediterranean-Middle East subtype. *Journal of Human Genetics* **48**: 275 - 277
- Muhammad HS, and MuhammadS. 2005. The use of *Lawsonia inermis* linn. (henna) in the management of burn wound infections. *African Journal of Biotechnology* **4**, 9: 934 - 937

- Nair P, Ibrahim E, Fareed A, Tadmouri GO. 2008. Glucose – Phosphate Dehydrogenase. *The Catalogue for Transmission Genetics in Arabs*, Center for Arabic Genomic Studies. Dubai, UAE
- Parr H. 2004. Medical geography: critical medical and health geography? *Progress in Human Geography* **28**: 246 - 257
- Pinna A, Masia C, Solinas G, Zinellu A, Carta A. 2007. Glucose-6-Phosphate Dehydrogenase (G6PD) deficiency in anterior ischemic optic neuropathy. *Acta Ophthalmologica Scandinavica*. **85**: 240
- Raup P, Hassan AJ, Varughese M, Kristiansson B. 2001. Henna causes life threatening haemolysis in glucose-6-phosphate dehydrogenase deficiency. *Archive of the Diseases of Childhood*. **85**: 411-412
- Rubens, A. 1967. *A History of Jewish Costume*. Funk and Wagnalls: New York.
- Saksena J. 1979. *Art of Rajasthan, Henna and Floor Decorations*. Sundeep Prakashan: Delhi, India
- Scurlock J and Andersen B. 2005. *Diagnoses in Assyrian and Babylonian Medicine: Ancient Sources, Translations and Modern Medical Analyses*. University of Chicago Press: Chicago.
- Simoons FJ. 1998. Malaria as a clue to understanding the history of favism and its bearing on the favism hypothesis. *International Journal of Anthropology*. **13**: 3-4, 257 – 263.
- Smith A. 2007. Century-scale holocene processes as a source of natural selection pressure in human evolution: Holocene climate and the human genome project. *The Holocene* **17**, **5**: 689 – 695.
- Soker M, Devecioglu C, Haspolat K, Dikici B, and Dogru O. 2000. Henna induced acute hemolysis in a G6PD-deficient patient: a case report. *International Pediatrics* **15**, **2**: 114-116.
- Tripathy V and Reddy BM. 2007. Present status of understanding on the G6PD deficiency and natural selection. *Journal of Postgraduate Medicine*, **53** (3): 93 - 202
- Westermarck E. 1926. *Ritual and Belief in Morocco Vols 1 & 2*. Macmillan and Company, Limited: London, UK
- Ya-Xia, Z, Suetake T, and Tagami H. 1999. Number of cell layers of the stratum corneum in normal skin – Relationship to the anatomical location on the body, age, sex, and physical parameters. *Archives of Dermatology Research*. **291**: 555 – 559

Zinkham WH and Oski FA. 1996. Henna: A potential cause of oxidative hemolysis and neonatal hyperbilirubinemia. *Pediatrics* **97**: 707-709.

Zinkham WH and Oski FA. 1996. Henna: a potential cause of oxidative hemolysis and neonatal hyperbilirubinemia *Pediatrics supplement* **394**: 58 – 76